

# P.E.T. CASE OF THE MONTH

David W. Seldin, M.D. Franklin Square Hospital Center December 2004

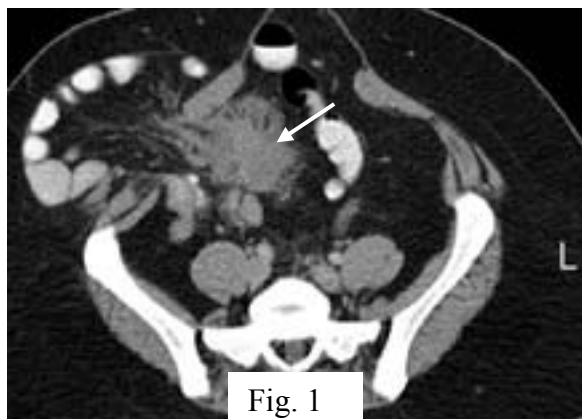


Fig. 1

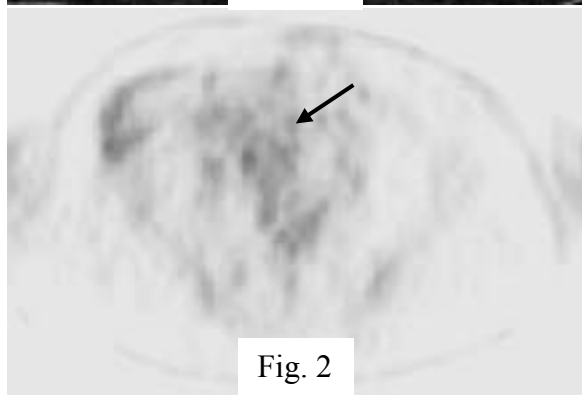


Fig. 2

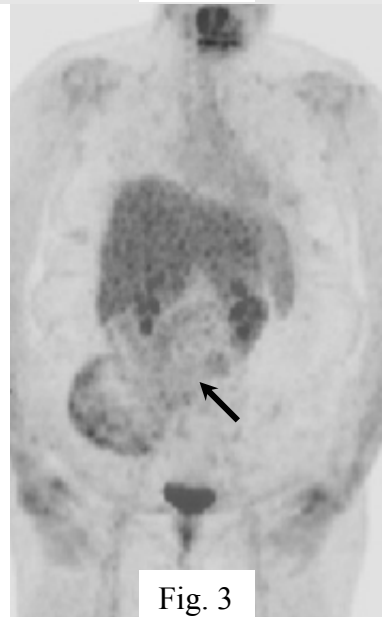


Fig. 3

This 26 year old woman with familial adenomatous polyposis (FAP) and colon carcinoma had a total colectomy three years earlier, followed by chemotherapy and subsequent small bowel resection for obstruction. She then presented with increasing abdominal pain. Her right lower quadrant ileostomy was functioning normally. An abdominal CT scan (Fig. 1) showed non-obstructed herniation of small bowel and a tumor (arrow) underlying the site of her pain.

A PET scan was obtained (Figs. 2 and 3) which showed low level uptake in the tumor mass, only slightly above background levels, suggestive of a benign process. No other areas of abnormal FDG uptake were present.

A biopsy of the mass performed during exploration to evaluate for bowel obstruction showed that the mass was a **desmoid tumor**.

**How did the PET help?:** Patients with familial adenomatous polyposis may postoperatively develop desmoids (aggressive benign fibrous neoplasms), which may be life-threatening if vital structures are encased and which is the cause of death in about 1/5 of FAP patients. Both surgical and medical therapies have a relatively low success rate. The PET was correct in determining that the abdominal masses were probably benign, making unlikely entities such as metastases from the patient's original colon carcinoma or a gastrointestinal stromal tumor (GIST), which might have been more amenable to therapy.

Recent studies have shown that FDG PET has good sensitivity for both recurrent colorectal carcinoma and GIST.

(1) J Nucl Med 2003;44:1784-1788

(2) J Nucl Med 2004;45:17-21

MedStar PET Services 410-933-2290  
Gabriel Soudry, M.D. 443-777-7492

This case and previous ones can be seen at  
[www.petcases.com](http://www.petcases.com)